

ACNE IN HALOGEN REMEDIES

Dr Gheorghe Jurj, MD, Dsc

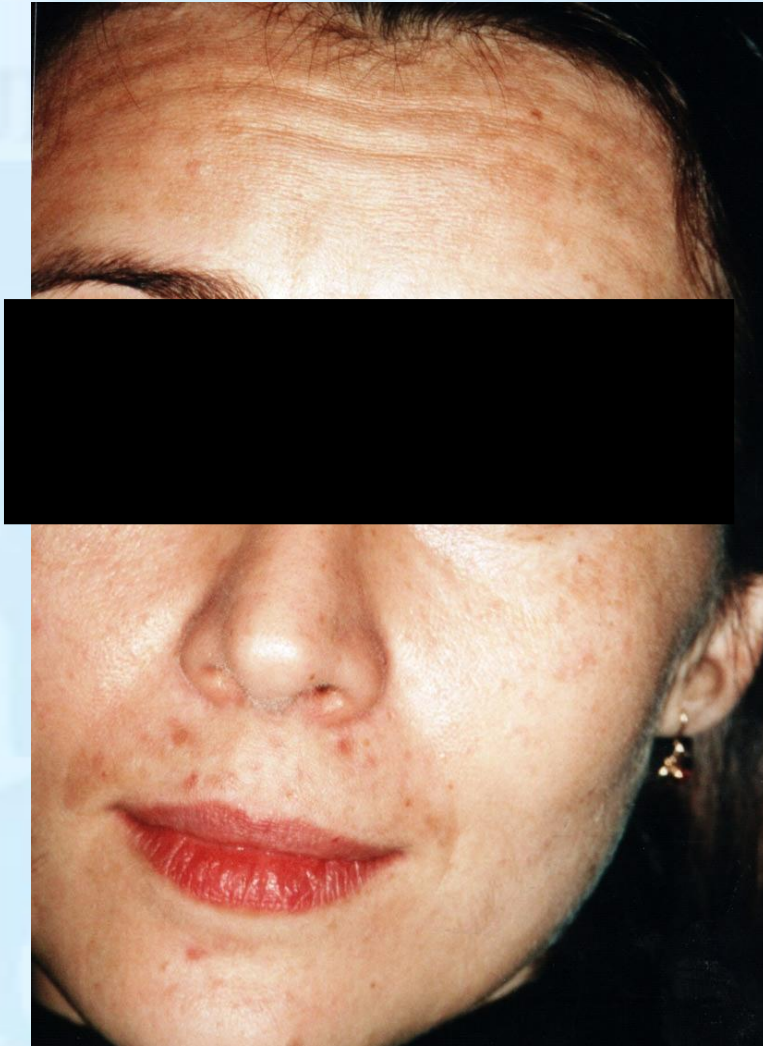Course: Visual Semiology

XXIX Brazilian Congress of Homeopathy

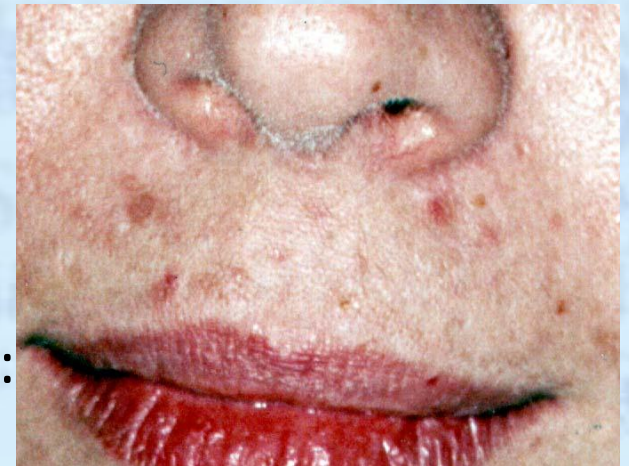São Paulo, 2008

NATRUM MURIATICUM

Mild follicular eruption on the edge of hair

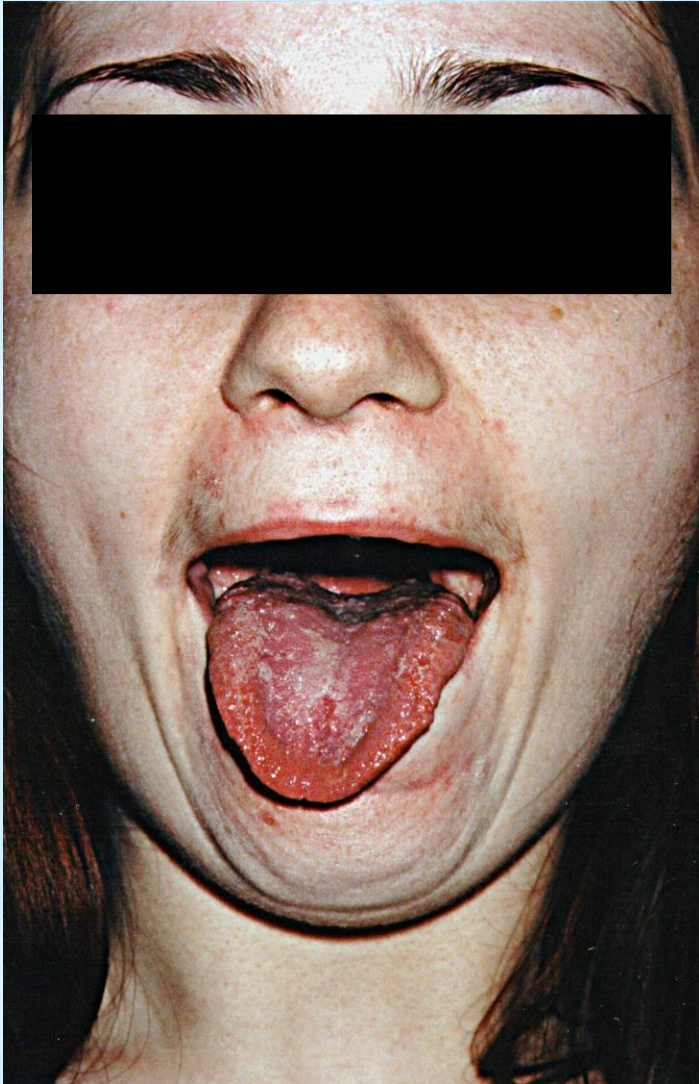


Localization:
subnasal



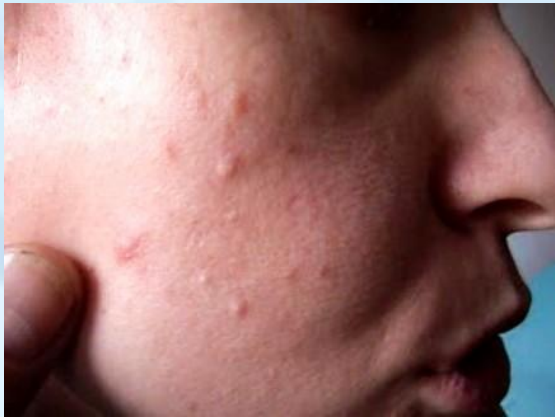Cracked lips

NATRUM MURIATICUM

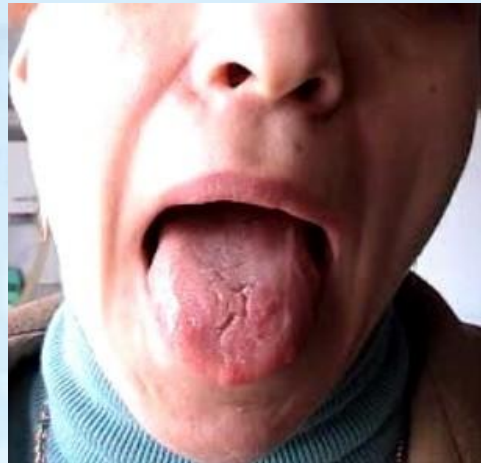
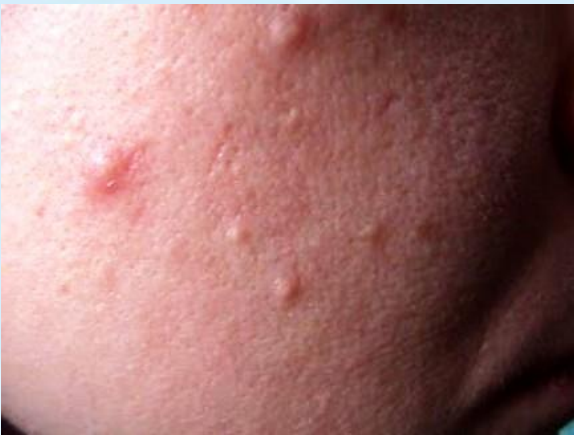
- Allergic rhinitis
- Subcutaneous micronodules on forehead
- Pimples over upper lip
- Mapped tongue

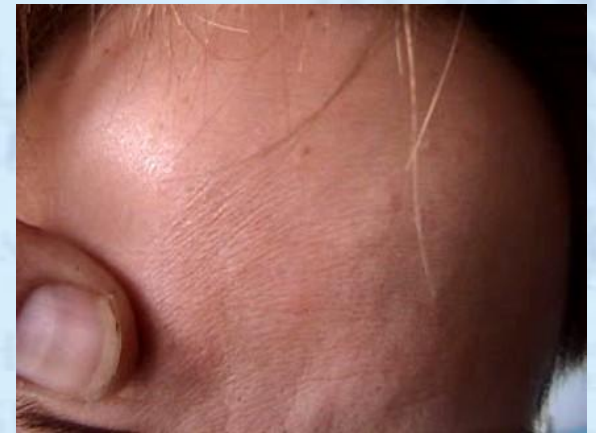NATRUM MURIATICUM



- Amenorrhea
- Non inflammatory micronodules



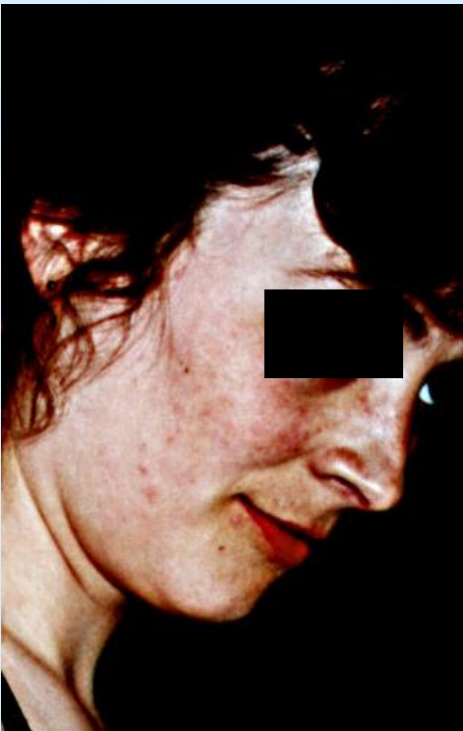- Mapped tongue
- Sinuous cracks



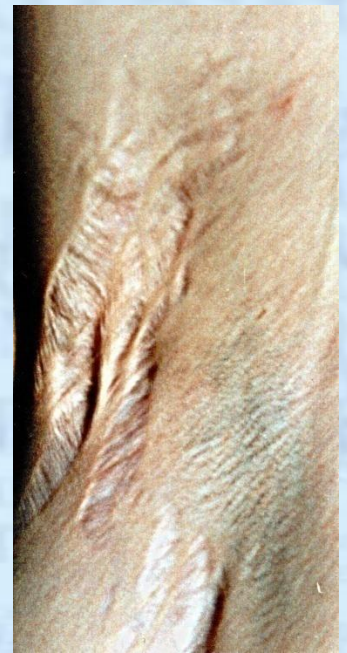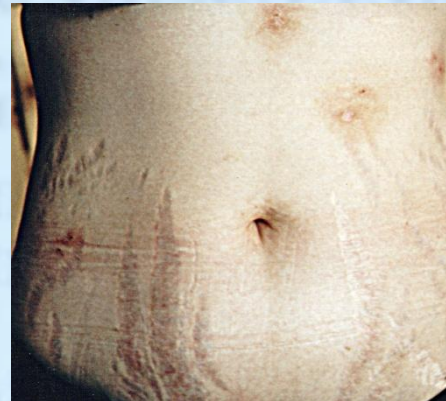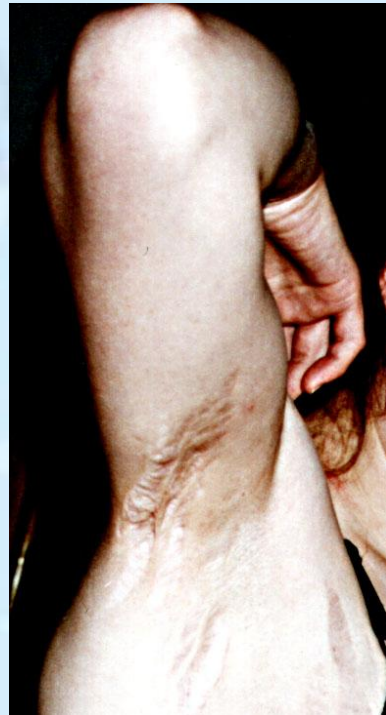- Oily skin

FLUORICUM ACIDUM

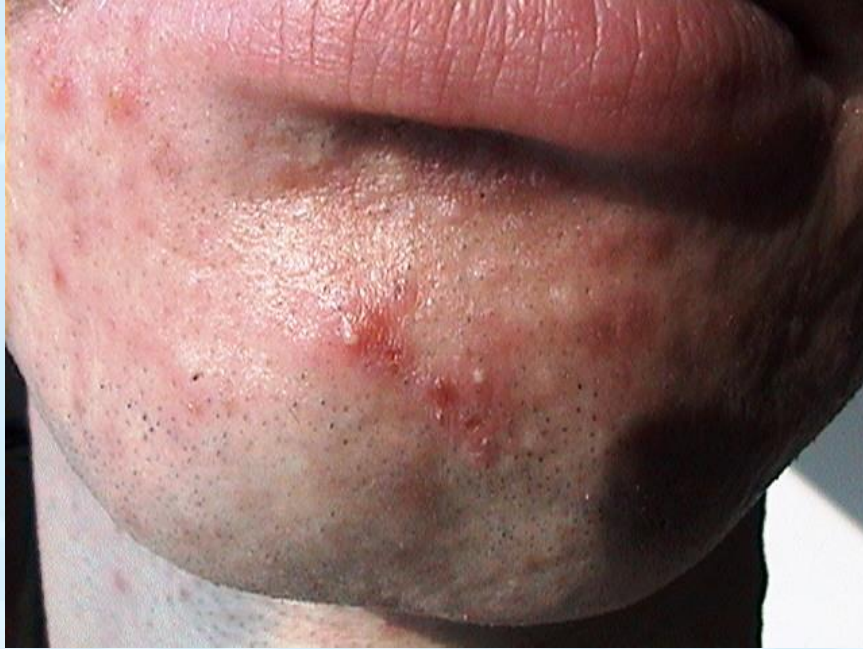SEVERE STRETCH MARKS



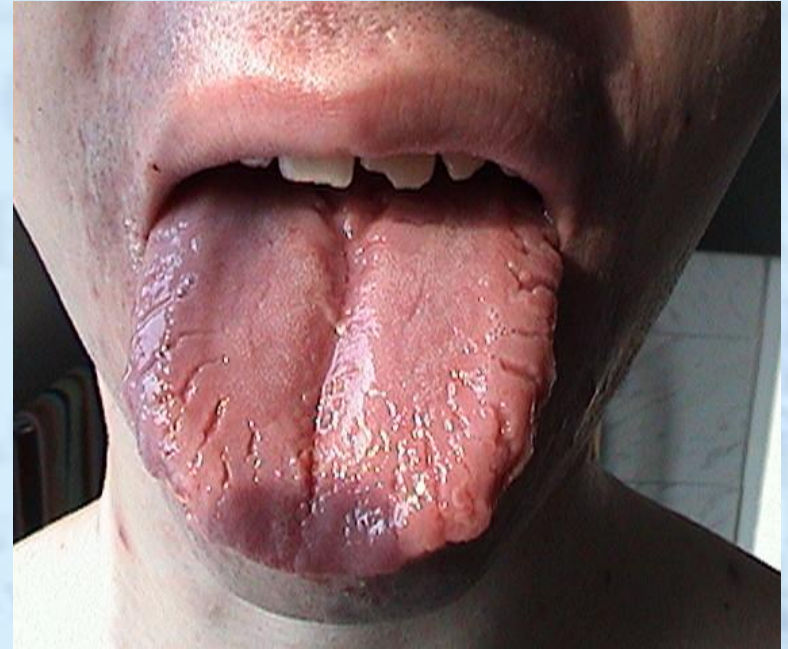FACIAL ACNE



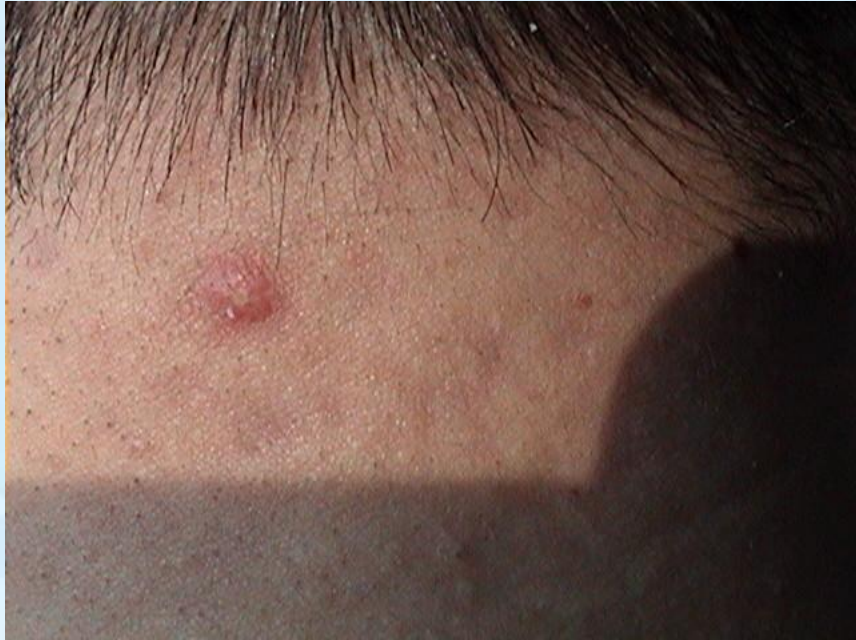FLUORICUM ACIDUM



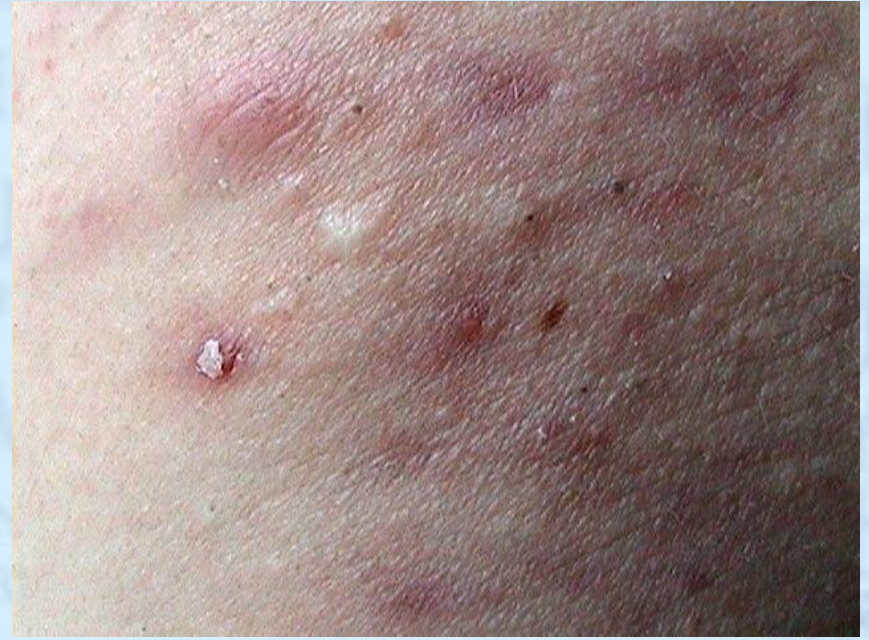Inflamed follicles; pustules
Multiple subcutaneous nodules,
sometimes painful



Medial cracks; cracks in all directions

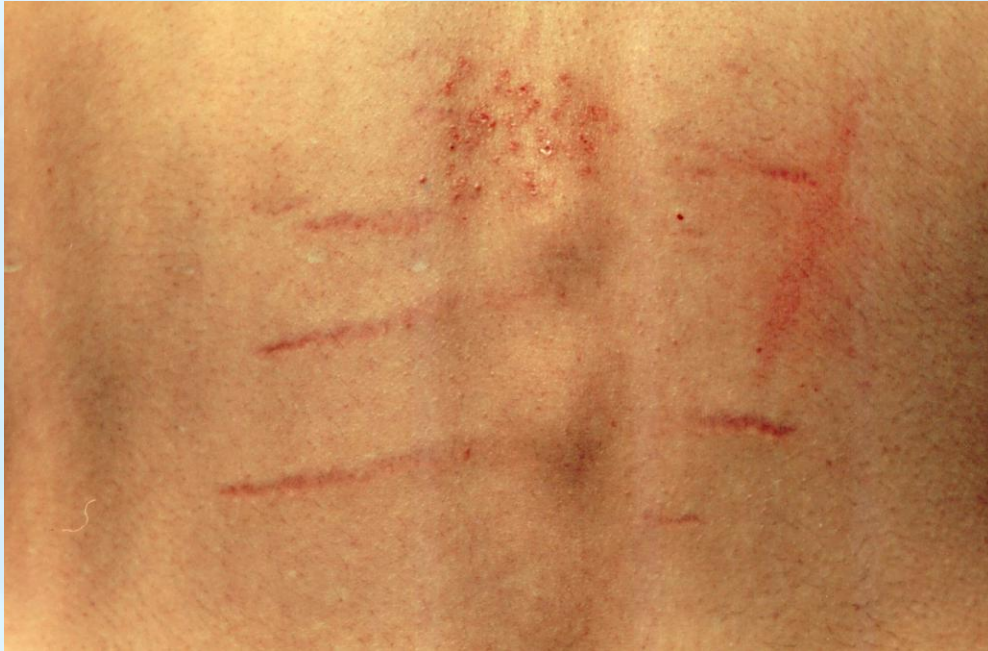

Pustule on edge of hair

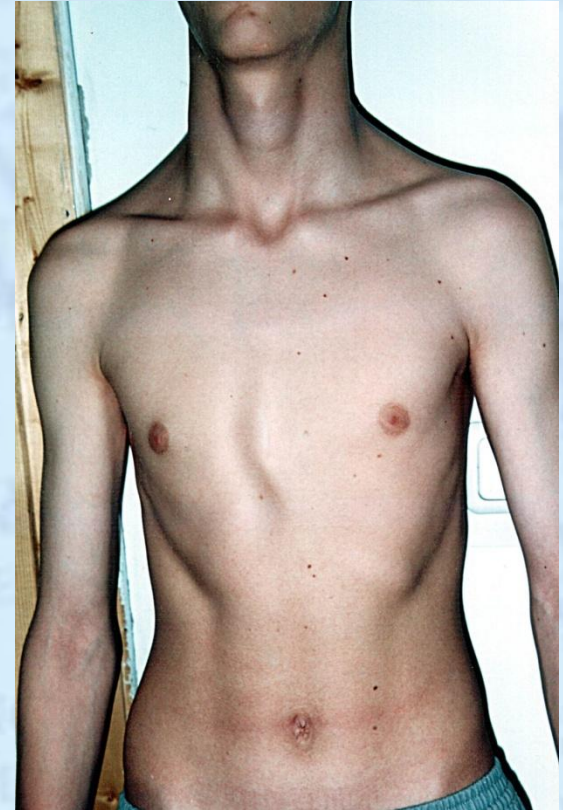

Micronodules and comedones

FLUORICUM ACIDUM

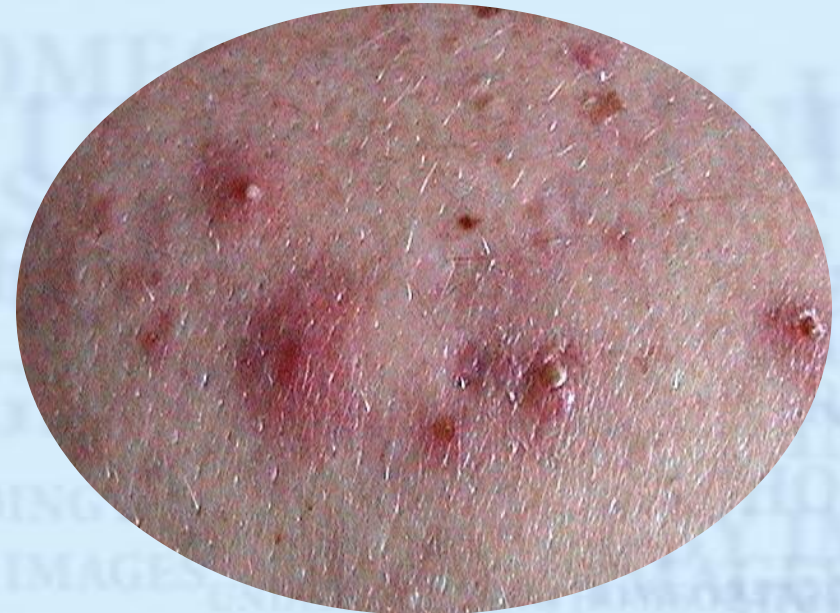
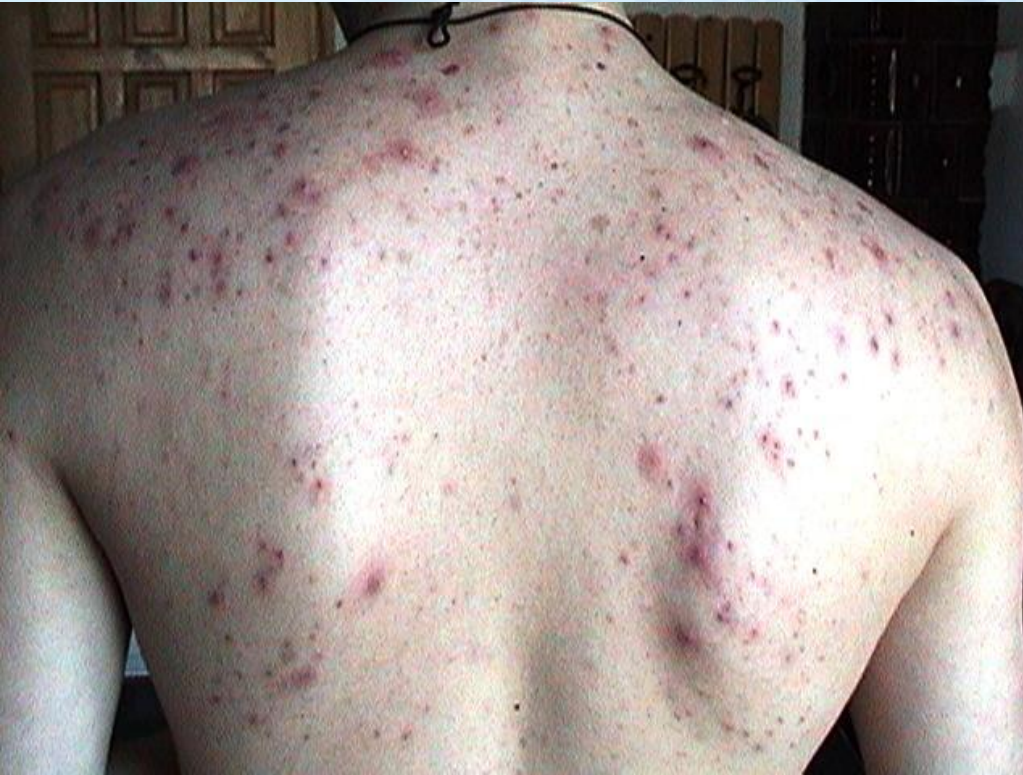
Pimples are very close to each other
Stretch marks on the back, on a thin individual



Deformity of sternum,
asymmetry of medial line

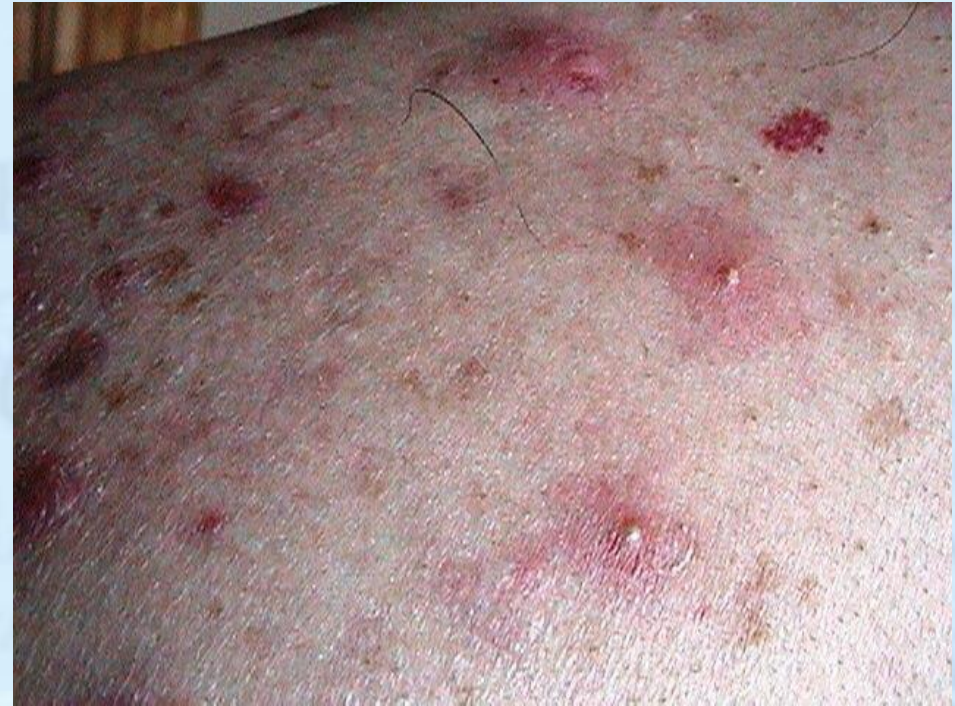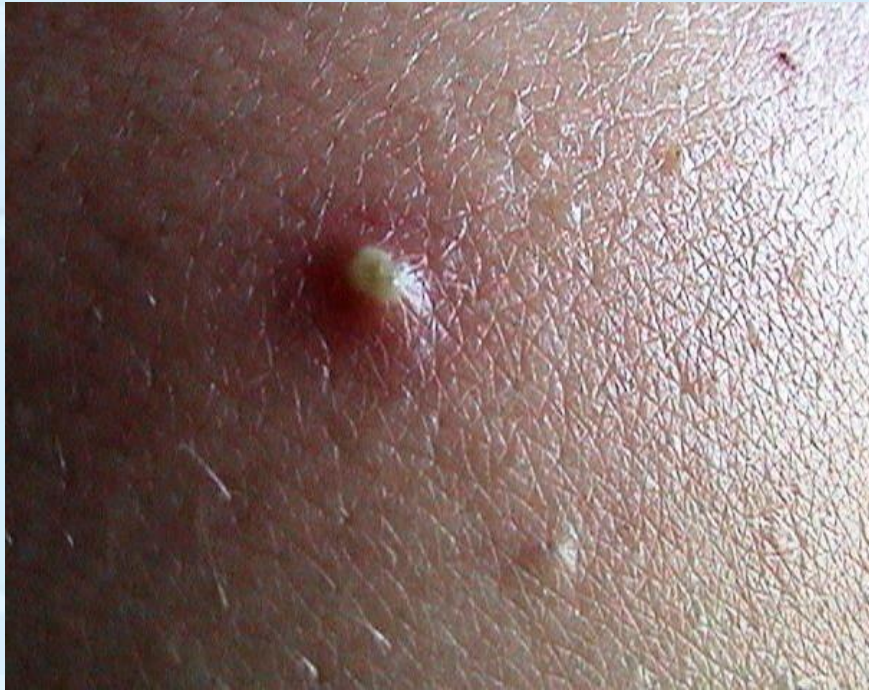KALIUM BROMATUM



Nodules and pustules are larger and deeper

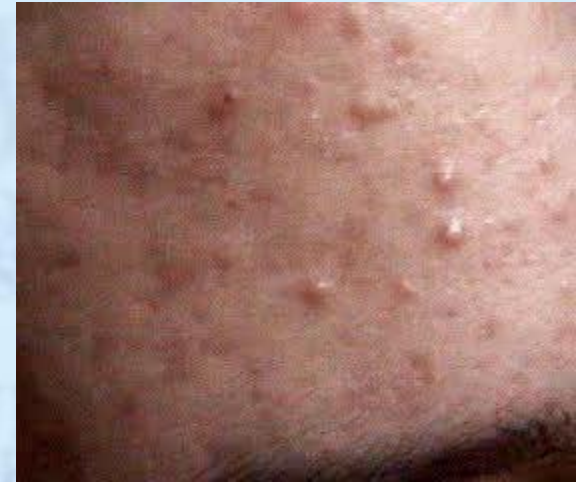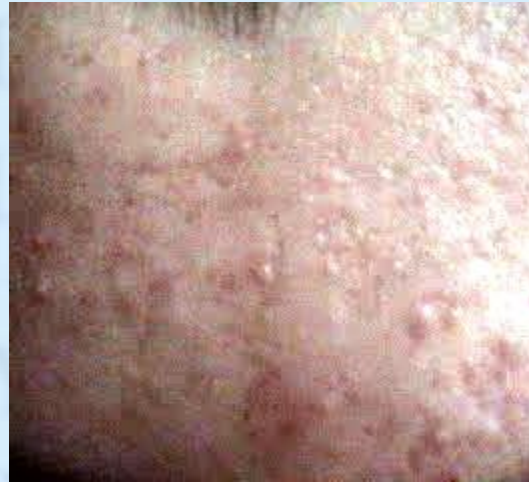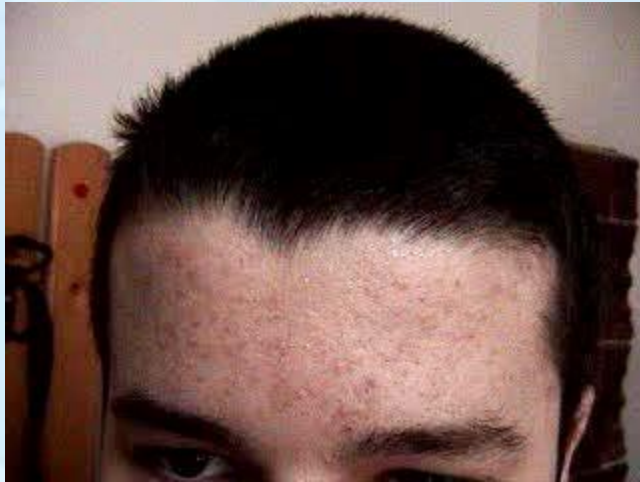A History of Acne:

- Nodules
- Inflammation
- Pustules
- Scars



- Skin looks dirty and rough
- Lesions progress in depth
- Hypo and hyperpigmented scars

KALIUM BROMATUM



- Autist patient, with compulsive behavior
- Forehead full of folliculitis, micronodules very close to each other

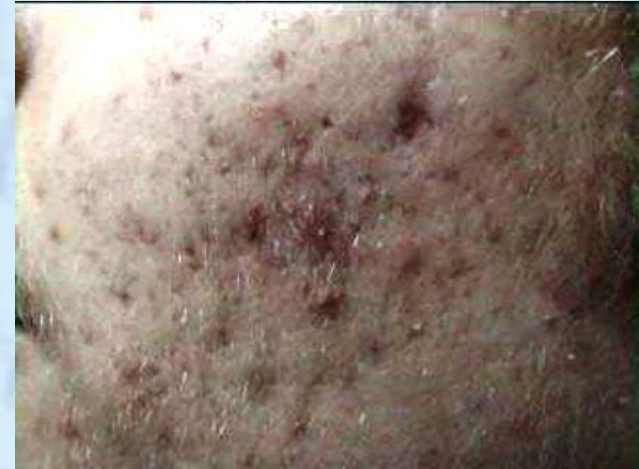
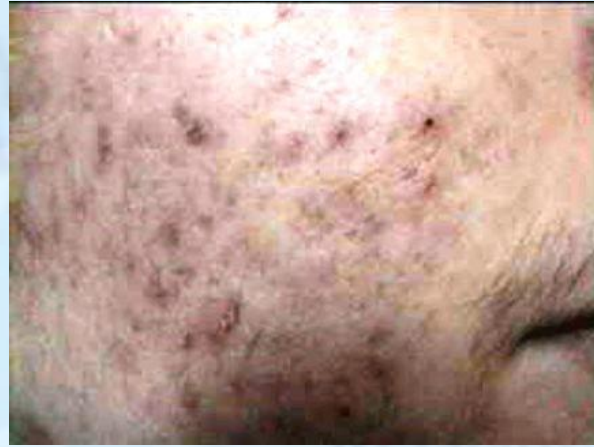
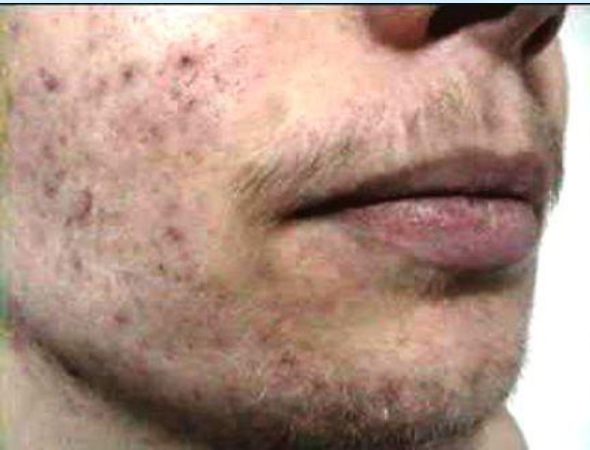Concomitant: constant agitation of hands

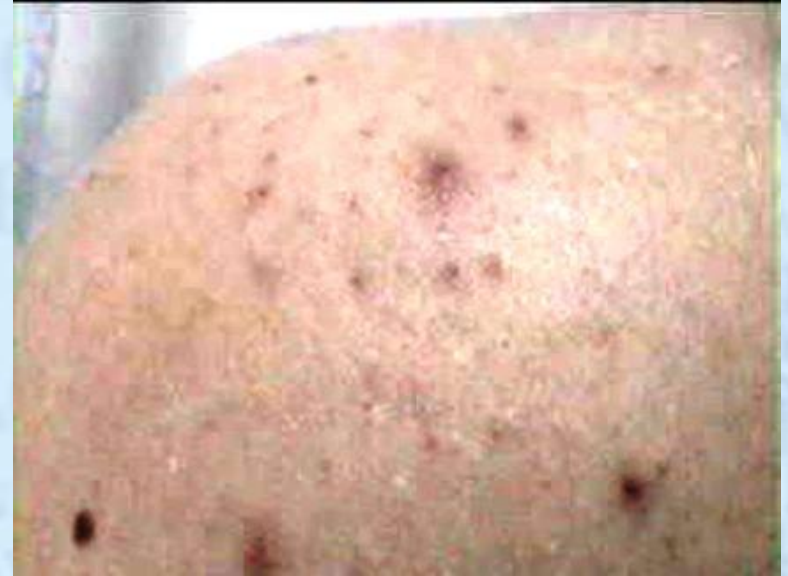
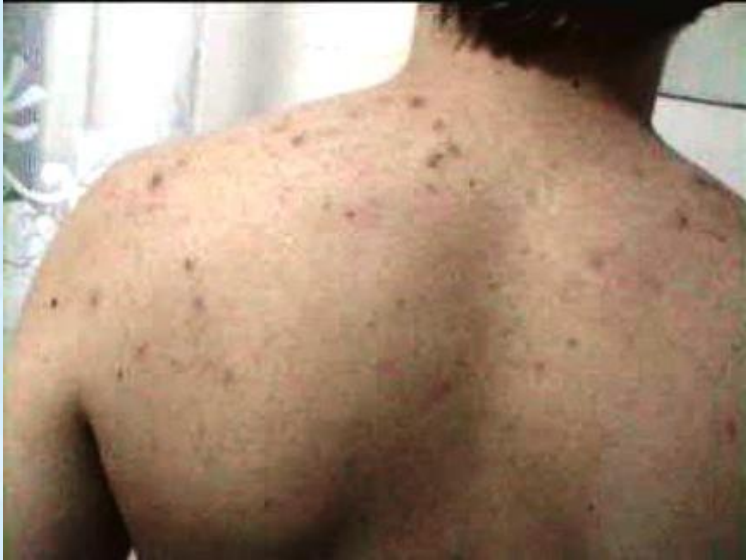
Compulsion to touch things

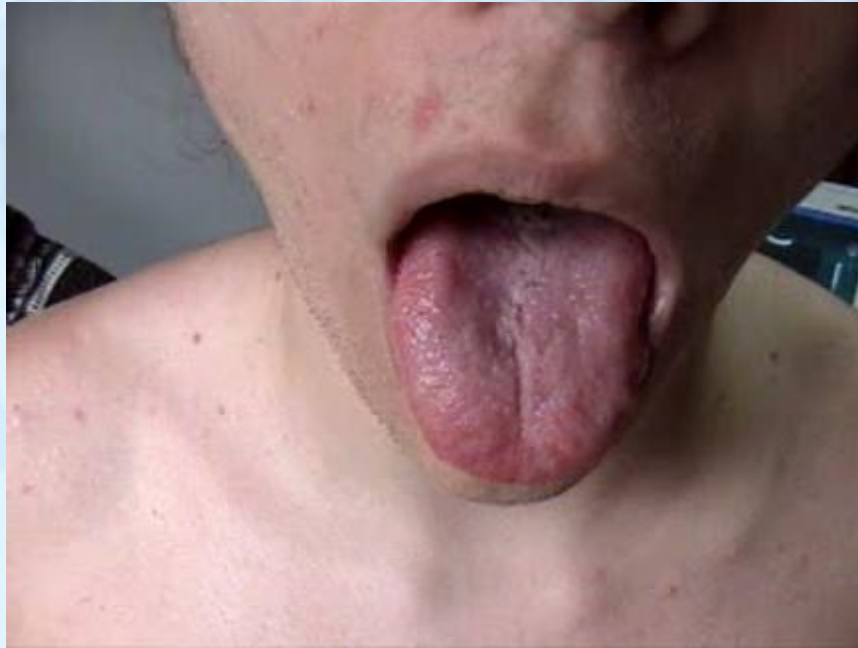RADIUM BROMATUM



- Patient with multiple sclerosis
- Everything is more severe, deeper, more toxic
- Deep acne, painful, bleeding, leaves deep and deforming scars



- Multiple deep pustules; bleeding



Asymmetry of medial line